

Management of progressive pseudoexfoliative glaucoma with low intraocular pressure

Gulizar Demirok¹, Guner Uney¹, Selma Uzman¹, Umay Guvenc²

ABSTRACT

A 58-year-old female patient diagnosed with pseudoexfoliative glaucoma (PEG) in the left eye had full vision in both eyes, and intraocular pressure (IOP) was 12/15 mmHg with brimonidine-timolol fixed combination in the left eye. The mean retinal nerve fiber thicknesses were 93/56 μ m. There was pseudoexfoliation in the left eye, the anterior chamber was shallow, its angle was Shaffer Grade 3. The mean deviation value in the left eye in the visual field was -26.59. Maximum medical treatment was initiated upon progression. The patient's IOP was 8/8 mmHg and progression was still continuing in the left eye on optical coherence tomography angiography (OCTA). Surgery was planned for her left eye and gonioscopy-assisted transluminal trabeculotomy (GATT) was performed. In the follow-ups, the left eye's IOP was 10 mmHg without medication and there was no progression. After GATT, peripapillary capillary density increased with OCTA and visual field enlargement was observed. Cataract surgery was performed in the first year after GATT.

Key Words: Low pressure glaucoma, pseudoexfoliative glaucoma, gonioscopy-assisted transluminal trabeculotomy, optical coherence tomography angiography

INTRODUCTION

Pseudoexfoliative glaucoma (PXG), is the most common form of secondary glaucoma worldwide with a worse prognosis than primary open-angle glaucoma (POAG) due to its poor response to medical therapy and faster progression.¹ The fact that is seen in the older age group, coexistence of cataract and glaucoma can be encountered more frequently.² In such circumstances, the surgical procedure and priority must be carefully considered. According to reports, pseudoexfoliation (PSX) on its own, without the contributory effect of raised intraocular pressure (IOP), is a risk factor for optic nerve head damage.^{3,4} The most important factor in the decision of glaucoma surgery is the presence of progression. For this purpose, visual field analyze and optical coherence tomography (OCT) should be evaluated together. The use of optical coherence tomography angiography (OCTA) to support structural tests has started to take its place in clinical practice, especially in cases with floor effect in OCT.⁵ The

literature on its use in progression follow-up is limited. Trabeculectomy is the most common filtering surgery for medically uncontrolled IOP in glaucoma patients, however, in low IOP conditions, it may carry the risk of hypotonia and accordingly early cataract development. Minimally invasive glaucoma surgeries (MIGS), are emerging as an alternative to trabeculectomy. Gonioscopy-assisted transluminal trabeculotomy (GATT) surgery with prolene suture is the most cost-effective non-invasive glaucoma surgery.⁶ However, due to possible postoperative IOP peaks, care should be taken when applying it to eyes with advanced glaucoma. Although IOP reduction was achieved with medical treatment in our case, surgery was required due to the progression detected by visual field analyze and OCTA, and GATT surgery was performed. In our case report, it is aimed to discuss the principles and results of surgical selection in cases with low intraocular pressure.

1- Assoc. Prof. Ankara Training and Research Hospital, Ophthalmology Department, Ankara, Türkiye

2- MD. Ankara Training and Research Hospital, Ophthalmology Department, Ankara, Türkiye

Received: 16.05.2023

Accepted: 31.05.2023

TJ-CEO 2024; 1: 41-45

DOI: 10.37844/TJ-CEO.2024.1.7

Correspondence Address:

Umay Guvenc
Ankara Training and Research Hospital, Ophthalmology Department,
Ankara, Türkiye

Phone:

E-mail: umay.guvenc@gmail.com

CASE PRESENTATION

A 58-year-old female patient was referred to our glaucoma unit with the diagnosis of PXG in her left eye. There was no family history of glaucoma and no systemic disease. The patient had a best-corrected visual acuity of 20/20 in the both eyes. IOPs were 12/15 mmHg with brimonidine-timolol fixed combination (BTFC) for left eye. The mean optic nerve fiber layer thickness was 93/56 μm with OCT (Figure 1). The left eye had pseudoexfoliation, a shallow anterior chamber, and a Shaffer Grade 3 angle. There was no pathology detected on the right eye. In visual field analyze, the mean deviation of the left eye was -26.59 and the central visual field was relatively clear. Upon detection of progression in the follow-up of the patient, maximum medical treatment was started gradually for the left eye. IOP was 8/8 mmHg with latanoprost in the right eye, BTFC, latanoprost and brinzolamide in the left eye. Despite the patient's low IOP values, upon detection of progression on OCTA in the left eye (Figure 2), surgery was planned and GATT was performed. During the follow-ups, IOP of the left eye was 10 mmHg without medication and an increase in capillary density was observed in OCTA (Figure 3). Visual field examination revealed a decrease in false negativity and an improvement (Figure 4). Our patient underwent uncomplicated cataract surgery using

the phacoemulsification technique with acrylic intraocular lens implantation, in the first year after GATT.

CONCLUSION

Pseudoexfoliation, is a risk factor for retinal nerve fiber damage.⁴ The association of PSX with neurodegenerative diseases supports this damage.⁷ In PXG, the continuation of progression, despite adequate IOP reduction requires that structural and functional tests be at the forefront besides IOP measurement in the follow-ups of the cases. In advanced glaucoma, visual field analyze becomes gradually important in follow-ups because of the floor effect with OCT.⁸ OCTA, on the other hand, has recently been studied in patients with glaucoma, as a non-invasive, high-resolution, fluorescence-free angiography technique.⁹ It allows the examination of vessel density in different layers of the retina, including the macula and optic nerve head by laser light reflectance of the surface of moving red blood cells.¹⁰ Düzova et al.¹¹ found that vascular density values were lower in glaucoma patients compared to normal individuals, and also there is a strong correlation between structural and functional tests and vessel density values. In the study, it was also shown that the vessel density in PXG is lower than in POAG.¹¹ While the literature data on the use of OCTA for follow-ups of glaucoma progression is limited, we believe that OCTA may be valuable in patients

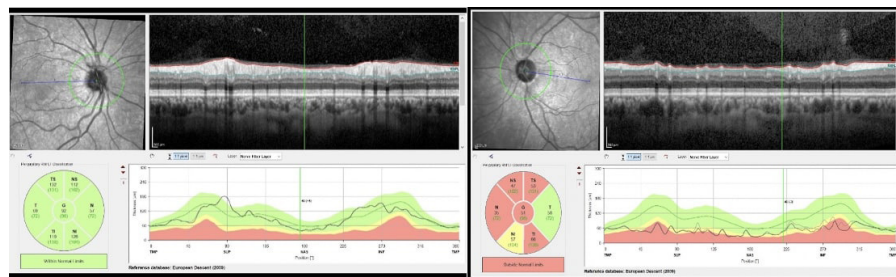


Figure 1: The mean optic nerve fiber thickness values of both eyes on OCT

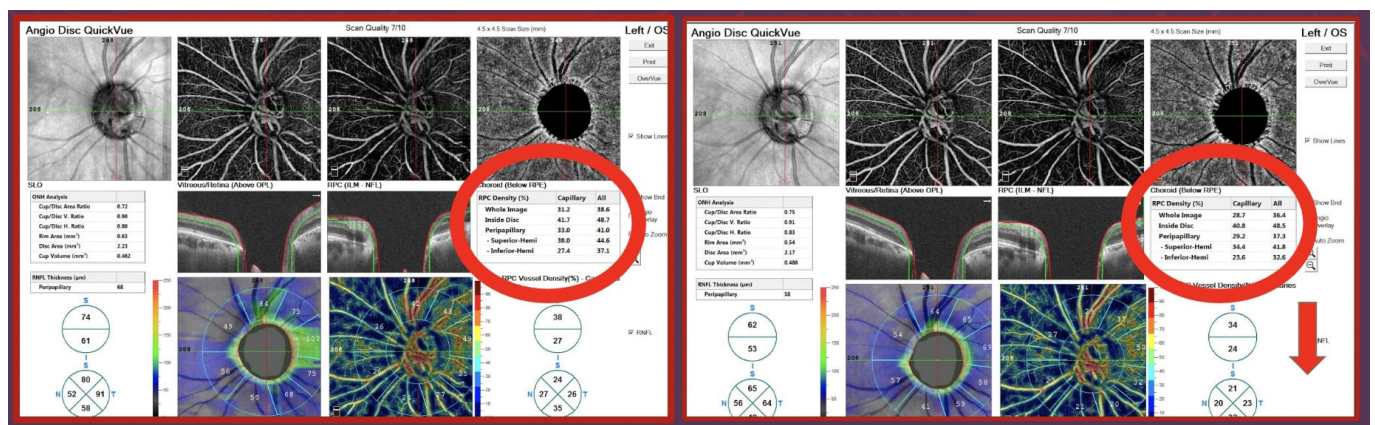


Figure 2: OCTA image showing progressive decrease in peripapillary capillary density in the left eye

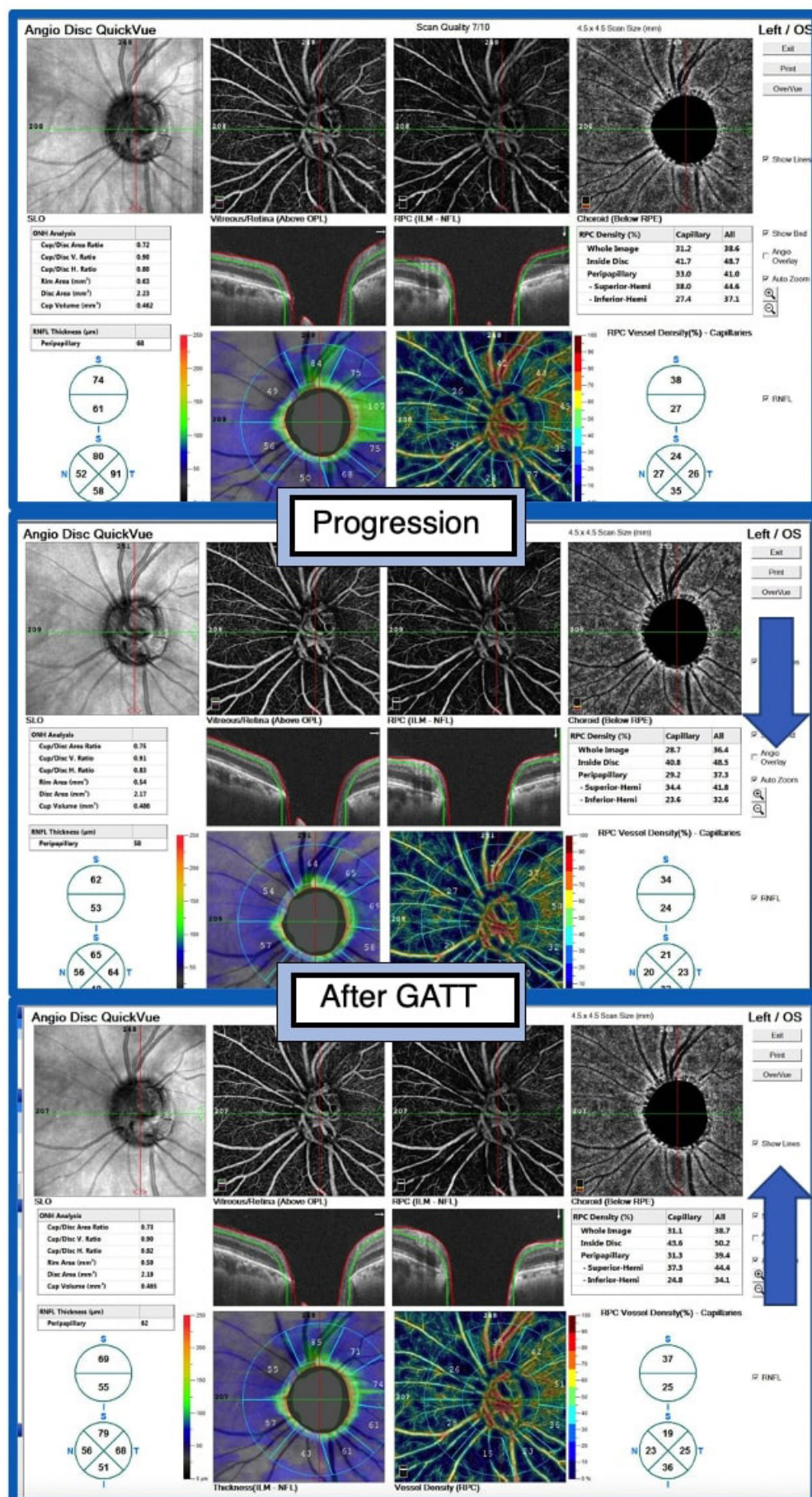


Figure 3: Left eye OCTA images showing that peripapillary capillary density decreased during progression and followed by an increase after GATT surgery

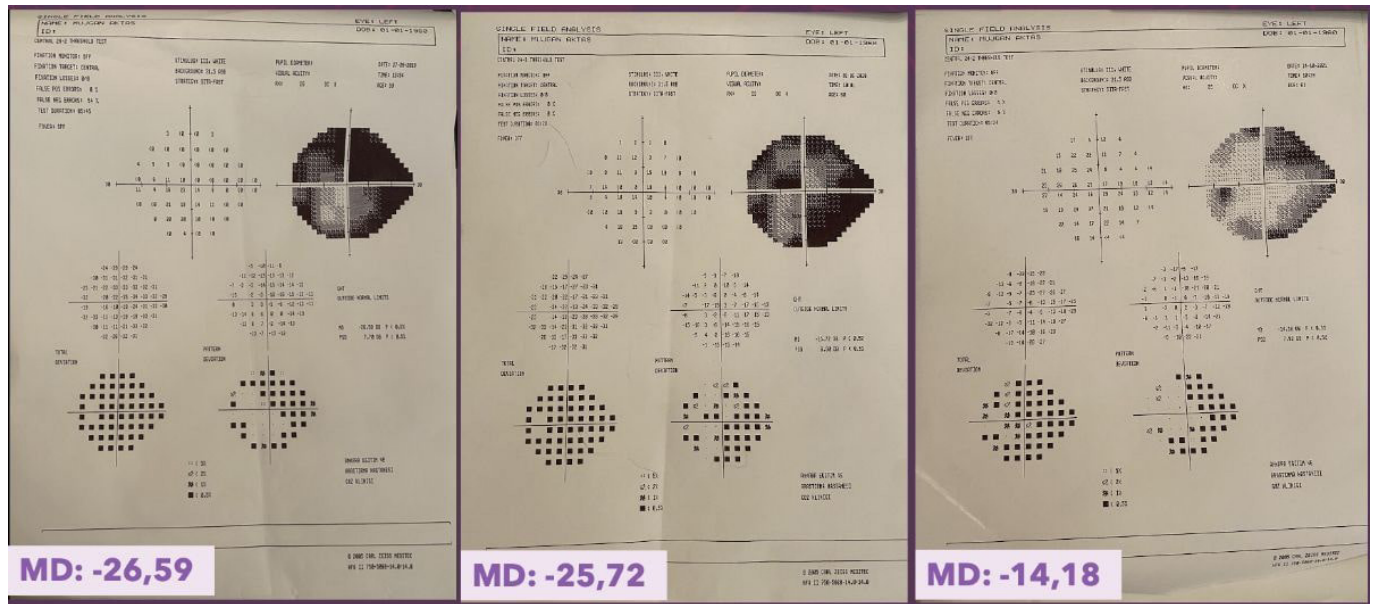


Figure 4: Visual field analysis of the left eye that showed improvement after GATT surgery

with floor effect on OCT, based on the idea that nerve fiber loss may lead to decreased blood supply surrounding the nerves. In our case, both the floor effect on OCT scans and high false negativity in the visual field analyzes necessitated considering OCTA in the follow-ups, thus, despite the low IOP, the decrease in vascular density could be detected and surgical planning could be performed.

Trabeculectomy is the most commonly performed glaucoma surgery however the emergence of cataract is one among the potential long-term side effects following this surgery.¹² The presence of PSX, on the other hand, is a significant risk factor for the acceleration of cataract progression.¹³ There are some studies that suggest cataract surgery has a detrimental impact on IOP control in trabeculectomy eyes.^{14,15} In our case, it can be stated that the risk of hypotony, shallow anterior chamber and cataract development after filtration surgery is increased due to the presence of low IOP and concomitant PSX. Therefore, we preferred to perform GATT surgery, which is less invasive, in our patient with a favorable angle. Although the IOP after GATT were similar as before the surgery but without treatment, as a hypothesis the PSX material clearance and increased outflow during GATT stopped the progression and an increase in capillary density was observed in OCTA. On the other hand, GATT surgery may be considered hesitant in advanced glaucoma because of nerve damage caused by postoperative IOP peaks, but in our case, the relatively large central island in the visual field facilitated the selection of GATT. Contrary to this reservation about performing GATT for advanced glaucoma, in a study this

surgery was presented as a safe and effective procedure for the treatment of moderate to advanced open-angle glaucoma.¹⁶

Cataract surgery with phacoemulsification applied to our patient in the first year of GATT and it did not adversely affect the success of GATT. In the follow-ups, IOP remained at 10 mmHg without any medication.

The visual field analyze is essential in the follow-ups of advanced glaucoma, and OCTA examinations, if available, is also valuable. In cases with PXG, progression may continue even if the IOP drops, and any surgeries performed in this patient group induce and accelerate the formation of cataracts. Cataract surgery, on the other hand, may adversely affect the success of penetrating glaucoma surgeries. All these should be taken into account when choosing surgical procedures. Our aim in presenting this case is to emphasize that there may be progression despite low IOP in eyes with PSX, and that OCTA are guiding and facilitate the surgical decision due to the floor effect in OCT in advanced glaucomas. Considering that surgical success may decrease with the management of possible complications of invasive glaucoma surgeries such as hypotonia and cataract development, it would be more rational to prioritize minimally invasive surgeries in eyes that progress despite low IOP. In our case, the postoperative slowdown of the progression despite the same level of IOP but without medication showed the positive effect of clearing the PSX material from the eye with increased outflow, independent of IOP. A more likely

positive effect is that IOP peak and diurnal control that could not be achieved with medications was achieved with GATT surgery.

REFERENCES

- Gillmann K, Meduri E, Niegowski LJ, et al. Surgical Management of Pseudoexfoliative Glaucoma: A Review of Current Clinical Considerations and Surgical Outcomes. *J Glaucoma* 2021;30:e32-e39. <https://doi.org/10.1097/IJG.0000000000001724>
- Plateroti P, Plateroti AM, Abdolrahimzadeh S, et al. Pseudoexfoliation Syndrome and Pseudoexfoliation Glaucoma: A Review of the Literature with Updates on Surgical Management. *J Ophthalmol* 2015;2015:370371. <https://doi.org/10.1155/2015/370371>
- Yarangümeli A, Davutluoglu B, Köz OG, et al. Glaucomatous damage in normotensive fellow eyes of patients with unilateral hypertensive pseudoexfoliation glaucoma: normotensive pseudoexfoliation glaucoma?. *Clin Exp Ophthalmol* 2006;34:15-9. <https://doi.org/10.1111/j.1442-9071.2006.01140.x>
- Toptan M, Simsek A. Evaluation of the Effect of Duration on Retinal Nerve Fiber Layer Thickness and Choroidal Thickness in Exfoliation Syndrome and Exfoliative Glaucoma. *Diagnostics (Basel)* 2023;13:314. <https://doi.org/10.3390/diagnostics13020314>
- Park HL, Hong KE, Shin DY, Jung Y, Kim EK, Park CK. Microvasculature Recovery Detected Using Optical Coherence Tomography Angiography and the Rate of Visual Field Progression After Glaucoma Surgery. *Invest Ophthalmol Vis Sci* 2021;62:17. <https://doi.org/10.1167/iovs.62.15.17>
- Velamala IP, Bharathi M. Gonioscopy Assisted Transluminal Trabeculotomy: A Boon to Developing Nations-A Systematic Review. *Semin Ophthalmol* 2023;38:178-82. <https://doi.org/10.1080/08820538.2022.2094715>
- Cumurcu T, Dorak F, Cumurcu BE, et al. Is there any relation between pseudoexfoliation syndrome and Alzheimer's type dementia? *Semin Ophthalmol* 2013;28:224-9. <https://doi.org/10.3109/08820538.2013.793726>
- de Moraes CG, Liebmann JM, Medeiros FA, et al. Management of advanced glaucoma: Characterization and monitoring. *Surv Ophthalmol* 2016;61:597-615. <https://doi.org/10.1016/j.survophthal.2016.03.006>
- Mwanza JC, Budenz DL. New developments in optical coherence tomography imaging for glaucoma. *Curr Opin Ophthalmol* 2018;29:121-9. <https://doi.org/10.1097/ICU.0000000000000452>
- Jia Y, Bailey ST, Hwang TS, et al. Quantitative optical coherence tomography angiography of vascular abnormalities in the living human eye. *Proc Natl Acad Sci U S A* 2015;112:E2395-E2402. <https://doi.org/10.1073/pnas.1500185112>
- Düzova E, Demirok G, Üney G, et al. Optical Coherence Tomography Angiography Findings in Primary Open-Angle and Pseudoexfoliation Glaucoma. *Turk J Ophthalmol* 2022;52:252-61. <https://doi.org/10.4274/tjo.galenos.2021.72654>
- Rajavi Z, Moezzi-Ghadim H, Kamrava K. The effect of trabeculectomy on cataract formation or progression. *J Ophthalmic Vis Res* 2009;4:84-9.
- AGIS (Advanced Glaucoma Intervention Study) Investigators. The Advanced Glaucoma Intervention Study: 8. Risk of cataract formation after trabeculectomy. *Arch Ophthalmol* 2001;119:1771-9. <https://doi.org/10.1001/archophth.119.12.1771>
- Sařaga-Pylak M, Kowal M, Zarnowski T. Deterioration of filtering bleb morphology and function after phacoemulsification. *BMC Ophthalmol* 2013;13:17. <https://doi.org/10.1186/1471-2415-13-17>
- Klink J, Schmitz B, Lieb WE, et al. Filtering bleb function after clear cornea phacoemulsification: a prospective study. *Br J Ophthalmol* 2005;89:597-601. <https://doi.org/10.1136/bjo.2004.041988>
- Aktas Z, Uçgul AY, Bektas C, et al. Surgical Outcomes of Prolene Gonioscopy-assisted Transluminal Trabeculotomy in Patients With Moderate to Advanced Open-Angle Glaucoma. *J Glaucoma* 2019;28:884-8. <https://doi.org/10.1097/IJG.0000000000001331>