

# Comparison of Retinal Nerve Fiber Layer Parameters Obtained Using Optical Coherence Tomography and Standard Automated Perimetry Results in Patients with Initial Diagnosis of Suspected Glaucoma

Raziye Dönmez Gün<sup>1</sup>, Burcu Yelmi<sup>1</sup>, Erdi Karadağ<sup>2</sup>, Şaban Şimşek<sup>3</sup>

## ABSTRACT

**Purpose:** To determine the relationship between retinal nerve fiber layer (RNFL) parameters obtained using optical coherence tomography (OCT) and the outcomes of standard automated perimetry (SAP) in patients with initial diagnosis of suspected glaucoma.

**Materials and Methods:** We retrospectively reviewed data of 147 eyes of 74 patients (aged 30-70 years) who were initially diagnosed as suspected glaucoma at ophthalmology outpatient clinic by an ophthalmologist between January 2017 and December 2019 and had at least six months of follow-up. We compared outcomes of visual field (VF) testing and RNFL thickness as measured by OCT, when available. We noted eyes diagnosed as glaucoma during follow-up.

**Results:** There were no significant correlations between SAP findings (Mean Deviation (MD), Pattern Standard Deviation (PSD)), and RNFL thickness (Mean, inferior, superior, nasal, temporal RNFL) obtained by using OCT (Spearman's rho  $p>0,05$ ) in patients with initial diagnosis of suspected glaucoma.

**Conclusions:** In our study, no significant correlation was found between VF findings and OCT parameters in patients with initial diagnosis of suspected glaucoma. Given the clinical presentation of these patients, it is important to assess the VF and OCT evaluations together in these patients in order to make definitive diagnosis.

**Keywords:** Suspected glaucoma, visual field, optical coherence tomography, retinal nerve fiber layer.

## INTRODUCTION

Glaucoma is a chronic, irreversible and progressive eye disorder and optical neuropathy characterized by loss of retinal nerve fibers<sup>1,2</sup> It is the second most common cause of blindness.<sup>3</sup> The early diagnosis of glaucoma is extremely important since it is a common disorder observed in a large population worldwide which leads severe loss of vision at time of diagnosis and irreversible damage.<sup>4</sup> The patient with suspected glaucoma defines an individual who has one or more clinical features and/or risk factor that increase likelihood of glaucomatous optic nerve degeneration or decreased vision in the future.<sup>5-7</sup> The patients having characteristics such as elevated intraocular pressure

(IOP), abnormalities in optic disc, visual field or RNFL; abnormal anterior chamber angle; and family history of glaucoma are those with suspected glaucoma. It may be sometimes challenging to make early diagnosis since it has various etiologies and clinical presentations.<sup>8</sup> Given that the diagnosis of glaucoma is a condition that affects quality of life and changes the life in an individual, the diagnosis should be made cautiously.<sup>9</sup> A limited examination with IOP measurement can lead overlook of diagnosis and even misdiagnosis.<sup>10</sup>

Glaucoma leads morphological damage by causing changes in optic nerve head whereas functional damage by causing visual field defects. The OCT and VF testing are useful in

1- MD, Department of Ophthalmology, Istanbul Kartal Doctor Lütfi Kırdar City Hospital, Istanbul, Turkey

2- Asist. MD, Department of Ophthalmology, Istanbul Kartal Doctor Lütfi Kırdar City Hospital, Istanbul, Turkey

3- Prof. MD, Department of Ophthalmology, Istanbul Kartal Doctor Lütfi Kırdar City Hospital, Istanbul, Turkey

Received: 15.12.2020

Accepted: 16.05.2021

Glo-Kat 2021; 16: 202-207

DOI: 10.37844/glauc.cat.2021.16.35

Correspondence Address:

Raziye Dönmez Gün

Department of Ophthalmology, Istanbul Kartal Doctor Lütfi Kırdar City Hospital, Semsî Denizer Street, E-5, 34890 Kartal, Istanbul, Turkey

Phone: +90 537 025 3770

E-mail: rdmstf84@gmail.com

the detection of such damages.<sup>4</sup> In the literature, there are studies suggesting positive correlation between perimetry indices and RNFL thickness as measured by OCT.<sup>10-12</sup> However, functional and structural damage may not occur concurrently. Visual field defects typical for glaucoma can occur a few years after onset of structural changes.<sup>13-15</sup>

The OCT is an essential imaging technique which is widely used in the diagnosis and follow-up of patients with glaucoma.<sup>16</sup> The OCT can help clinicians to determine whether there is a glaucoma-related damage in an eye when used as an ancillary diagnostic test in patients with suspected glaucoma and provide information required in decision-making process during glaucoma management.<sup>17</sup> In the presence of suspected optic nerve head cupping, the use of OCT to assess RNFL can provide further information for definitive diagnosis.<sup>17</sup> In glaucoma, characteristics visual field defects and retinal nerve fiber losses are seen.<sup>18,1</sup> Progressive visual field loss is a major marker for discriminating true pathology from glaucoma suspicion.<sup>7</sup> In our study, it was aimed to evaluate whether there is a correlation between these two tests which are valuable in the definitive diagnosis of patients with suspected glaucoma.

## MATERIALS AND METHODS

We retrospectively reviewed data of 147 eyes of 74 patients (aged 30-70 years) who were initially diagnosed as suspected glaucoma at ophthalmology outpatient clinic by an ophthalmologist between January 2017 and December 2019 and had at least six months of follow-up. The study was approved by Ethics Committee. The study was conducted in accordance to tenets of Helsinki Declaration.

The study included patients aged 30-70 years who had visual acuity  $\geq 20/25$ , refractive error 5 D (spherical equivalent) and astigmatism  $< 3$  D and clear optic visualization (no marked lens sclerosis or cataract, no examination finding that may hamper fundus imaging). In the study, the patient must have at least 6 months of follow-up after diagnosis of suspected glaucoma. The cases with history of ocular trauma, previous history of ocular surgery, systemic disease (diabetes mellitus, hypertension etc.) that may affect eyes and cases in which comprehensive ophthalmological examination, perimetry or optical coherence tomography cannot be performed due to any reason were excluded. The patient should have at least one of the following characteristics:<sup>5</sup>

- IOP elevation
- Optic nerve head image or RNFL assessment suggesting glaucomatous injury

- Un explained visual field defect compatible with glaucoma
- Abnormal anterior chamber angle
- Family history of severe glaucoma and other risk factors

In all patients, comprehensive ophthalmological examination (clinical history, best-corrected visual acuity [BCVA] as assessed by Snellen chart and transformed to logMAR), biomicroscopic anterior segment and fundus examination, gonioscopy, IOP measurement by Goldmann applanation tonometry (mean of 3 highest IOP measurement during follow-up for suspected glaucoma) and central corneal thickness as measured by topography (Sirius Topography Device, CSO, Frenze, Italy) were recorded. In addition, optic nerve head assessment and cup: disc ratio were recorded. In all patients, at least 3 reliable (loss of fixation  $< 15\%$ , false-positive and false-negative rates  $< 15\%$ ) 30/2 visual field tests (Carl Zeiss, Humphrey® 745i Field Analyzer, Jena, Germany) were required for inclusion and data from most reliable test were included to statistical analyses. For OCT, the dilatation was achieved by 1% tropicamide and RNFL measurements were performed using OCT (Nidek RS-3000 Advance®, Aichi, Japan) by same experienced operator. For peripapillary RNFL thickness measurement, screening ring (3.4 mm in diameter) was placed by centering optic disc and the patient was asked not to move his/her head. The RNFL measurements (mean, inferior, superior, nasal and temporal RNFL thicknesses) were recorded retrospectively. After diagnosis of suspected glaucoma, follow-up visits were performed by two ophthalmologists and it was noted that whether definitive diagnosis of glaucoma was made during follow-up.

## Statistical analysis

The normality of continuous variables were assessed using Shapiro Wilk test. Continuous variables are presented as mean, standard deviation, minimum-maximum and median while categorical variables are presented as frequency. The correlation between two continuous variable with skewed distribution was tested using Spearman's rho correlation. Statistical significance was set as 0.5. The statistical analyses were performed using MedCalc Statistical Software version 12.7.7 (MedCalc Software bvba, Ostend, Belgium; <http://www.medcalc.org>; 2013).

## RESULTS

Of the patients included, 55 (74.3%) were women while 19 (25.7%) were men. Mean age was  $50.57 \pm 12.2$  years. There was family history of glaucoma in 24 patients

(32%). During follow-up, 35 eyes (23.8%) were diagnosed as glaucoma. Table 1 presents demographic characteristics and number of eyes diagnosed with glaucoma.

Mean BCVA was  $0.008 \pm 0.035$  logMAR while mean IOP Was  $21.96 \pm 3.5$  mmHg. Mean central corneal thickness was  $560.4 \pm 37.2$   $\mu\text{m}$  while mean vertical c:d ratio was  $0.78 \pm 1.29$ . In the 30/2 visual field testing, mean MD was  $-1.76 \pm 1.5$  dB while mean PSD was  $2.19 \pm 1.5$  dB. On OCT, mean RNFL thickness was  $96.76 \pm 9.5$   $\mu\text{m}$  while it was  $125.56 \pm 17$   $\mu\text{m}$ ,  $123.03 \pm 15.87$   $\mu\text{m}$ ,  $68.88 \pm 12.26$   $\mu\text{m}$  and  $69.79 \pm 9.5$   $\mu\text{m}$  at inferior, superior, nasal and temporal quadrants. Table 2 presents ophthalmic examination findings and results of testing.

No significant correlation was detected visual field parameters (MD, PSD) and mean RNFL thickness and inferior, superior, nasal and temporal RNFL thicknesses (Spearman's rho;  $p > 0.05$ ) (Table 3) (Graphic 1).

Table 1: Distribution of demographic data.			
		N	%
Gender	Female	55	74,3
	Male	19	25,7
Family History	Positive	24	32,0
	Negative	50	66,7
Eye	Right	74	50,3
	Left	73	49,7
	N	Mean $\pm$ SD	Med. (Min-Max)
Age (years)	74	50,57 $\pm$ 12,2	51 (13-85)
SD: Standard deviation			

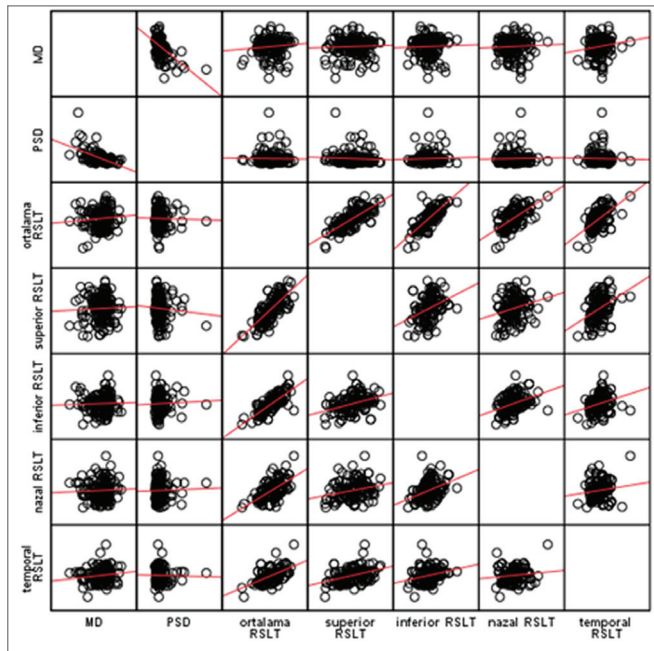
The visual field testing (Figure 1) and image of RNFL parameters by OCT in the same patient (Figure 2) are presented. The patient was 42-years old with family history of glaucoma. BCVA was 0.00 logMAR full in both eyes and IOP was measured as 21 mmHg in right eye and 21 mmHg in the left eye at presentation. The anterior chamber angle was open in both eyes. The central corneal thickness was 540  $\mu\text{m}$  in the right eye and 530  $\mu\text{m}$  in the left eye. The cup: disc ratio was 0.5 in both eyes. The patient had peripapillary atrophy in both eyes and was diagnosed with suspected glaucoma by an ophthalmologist.

## DISCUSSION

In our study, no significant correlation was found between RNFL thickness as measured by RNFL and visual field

Table 3: Comparison of visual field data and RNFL thickness as measured by OCT.			
		MD (dB)	PSD (dB)
Mean RSLT ( $\mu\text{m}$ )	r	0,085	-0,065
	p	0,306	0,432
Inferior RNFL ( $\mu\text{m}$ )	r	0,071	-0,024
	p	0,391	0,775
Superior RSLT ( $\mu\text{m}$ )	r	-0,015	-0,076
	p	0,854	0,359
Nazal RSLT ( $\mu\text{m}$ )	r	0,074	0,014
	p	0,373	0,869
Temporal RSLT ( $\mu\text{m}$ )	r	0,151	-0,088
	p	0,067	0,291
RNFL: Retinal nerve fiber layer, MD: Mean deviation, PSD: Pattern standart deviation.			

Table 2: Ophthalmic examination findings and results of evaluations in eyes included.			
	N	Mean $\pm$ SD	Med. (Min-Max)
BCVA (logMAR)	147	0,008 $\pm$ 0,035	0 (0-0,3)
IOP (mmHg)	147	21,96 $\pm$ 3,5	22 (11-29)
CCT ( $\mu\text{m}$ )	147	560,4 $\pm$ 37,2	560 (438-660)
Vertical c/d ratio	147	0,78 $\pm$ 1,29	0,5 (0-8)
MD (dB)	147	-1,76 $\pm$ 1,5	-1,33 (-7,05-1,55)
PSD (dB)	147	2,19 $\pm$ 1,5	1,9 (1,11-11,39)
Mean RNFL ( $\mu\text{m}$ )	147	96,76 $\pm$ 9,5	96 (67-119)
Inferior RNFL ( $\mu\text{m}$ )	147	125,56 $\pm$ 17	125 (84-182)
Superior RNFL ( $\mu\text{m}$ )	147	123,03 $\pm$ 15,87	124 (86-160)
Nazal RNFL ( $\mu\text{m}$ )	147	68,88 $\pm$ 12,26	69 (46-115)
Temporal RNFL ( $\mu\text{m}$ )	147	69,79 $\pm$ 9,5	70 (41-111)
CTT: Central corneal thickness, PSD: Pattern Standard Deviation, SD: Standard deviation, RNFL: Retinal nerve fiber layer, MD: Mean deviation, BCVA: Best Corrected Visual Acuity, IOP: Intra ocular pressure.			

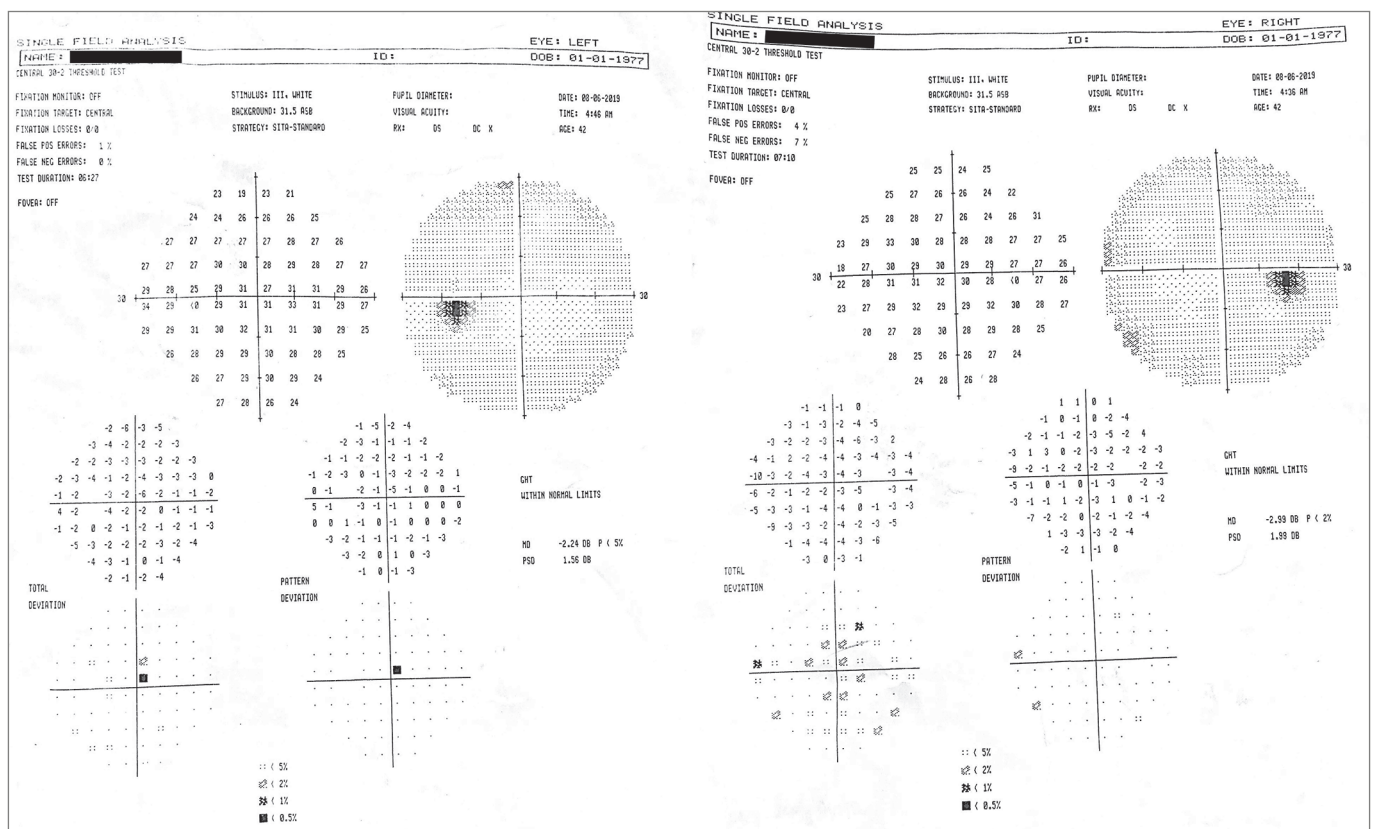


**Graphic 1:** Correlation between visual field parameters (MD and PSD) and mean RNFL thickness as well as RNFL thicknesses in inferior, superior, nasal and temporal quadrants.

parameters in patients with initial diagnosis of suspected glaucoma.

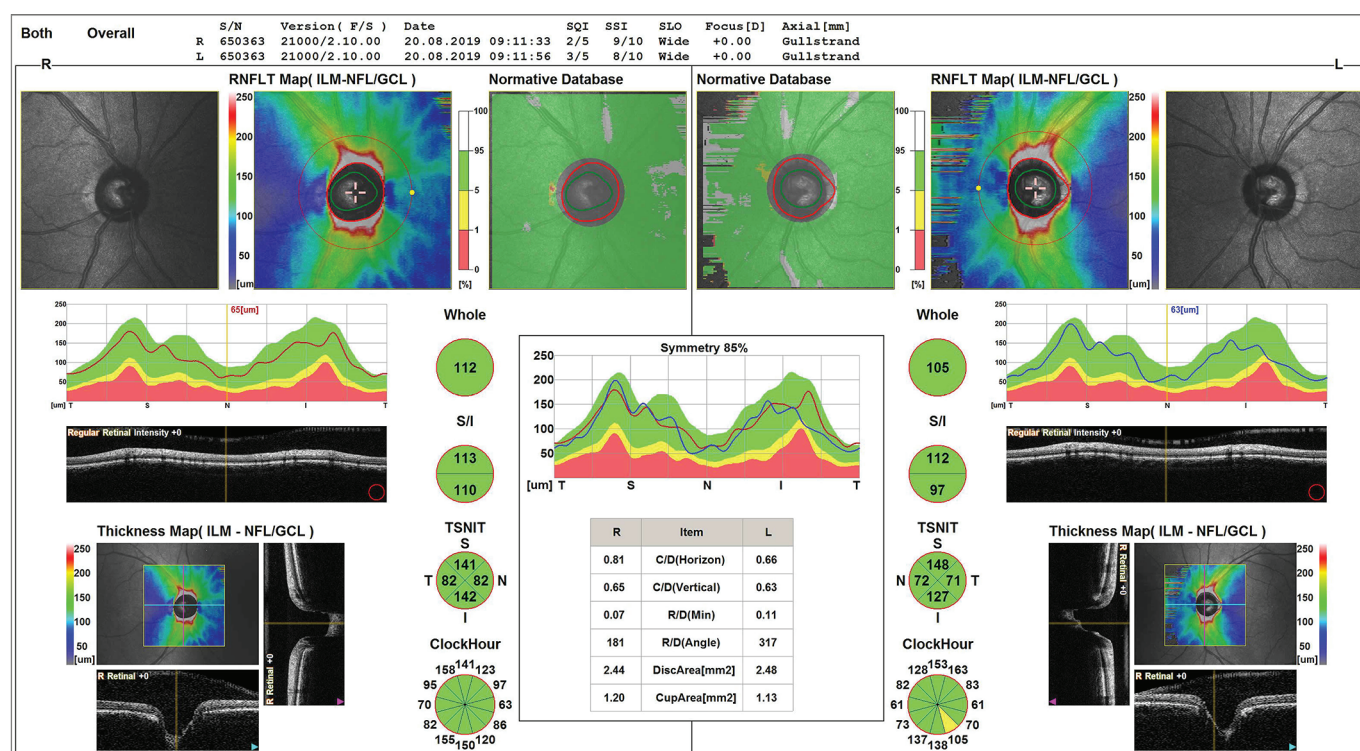
The OCT has become gold standard test for structural assessment of optic nerve head, RNFL and macular

ganglion nerve layer in glaucoma.<sup>19</sup> It has gained importance since the OCT measurements are better than previous modalities regarding sensitivity, selectivity and reproducibility.<sup>20</sup> Bayraktar et al. evaluated data from 113 eyes and 64 patients in their study on reproducibility of RNFL thickness measurements by OCT in patients with early glaucoma and suspected glaucoma.<sup>21</sup> Authors found that RNFL was  $82.3 \pm 11.4 \mu\text{m}$  whereas it was  $102.5 \pm 17.2 \mu\text{m}$ ,  $112.7 \pm 14.5 \mu\text{m}$ ,  $58.8 \pm 32.8 \mu\text{m}$  and  $65.2 \pm 29.6 \mu\text{m}$  in superior, inferior, temporal and nasal quadrants, respectively. In their study including 4 groups (normal eyes, eyes with ocular hypertension, eyes with suspected glaucoma and glaucomatous eyes), Lopez-Pena et al. evaluated associations between RNFL parameters as measured OCT and SOP parameters.<sup>12</sup> Authors found mean RNFL thickness in the group with suspected glaucoma were  $87,66 \pm 14,21 \mu\text{m}$  and  $104,19 \pm 22,64 \mu\text{m}$ ,  $115,64 \pm 22,08 \mu\text{m}$ ,  $60,84 \pm 11,98 \mu\text{m}$  and  $69,44 \pm 18,20 \mu\text{m}$  in superior, inferior, temporal and nasal quadrants, respectively.<sup>12</sup> In our study, these values were found as  $96,76 \pm 9,5 \mu\text{m}$ ,  $123,03 \pm 15,87 \mu\text{m}$ ,  $125,56 \pm 17 \mu\text{m}$ ,  $69,79 \pm 9,5 \mu\text{m}$  and  $68,88 \pm 12,26 \mu\text{m}$ , respectively. The RNFL thicknesses were higher in our study when compared to those reported by Bayraktar et al.<sup>21</sup> Given that 23.8% of the eyes included were diagnosed as glaucoma during follow-up, the eyes with normal RNFL thickness may have contributed to higher mean RNFL thickness in our study, resulting in higher mean



**Picture 1:** Visual field testing in a patient with suspected glaucoma.





**Picture 2:** RNFL parameters as measured by OCT in the same patient.

RNFL thickness level when compared to Bayraktar et al.<sup>21</sup> Although mean RNFL thickness in nasal quadrant were comparable to those reported by Lopez-Pena et al.,<sup>12</sup> mean RNFL thicknesses in remaining quadrants were slightly higher in our study. In the study by Lopez-Pena et al.,<sup>12</sup> the inclusion criteria was optic head nerve with glaucomatous morphology for all patients included to suspected glaucoma group; however, this was not an inclusion criteria although our study included patients with optic nerve head appearance suggesting glaucomatous damage. This may have lead higher mean RNFL thickness in our study.

Glaucoma is a group of diseases which show characteristic visual field defects and lead chronic, progressive optic neuropathy.<sup>18</sup> Although novel technologies have been introduced to facilitate diagnosis of glaucoma, the reference test is SOP to make definitive diagnosis of glaucoma in a patient.<sup>13, 22</sup> Although visual field testing is somewhat subjective, progressive loss of visual field is an important marker to discriminate definitive diagnosis of glaucoma from suspected glaucoma.<sup>7</sup> In our study, it was found that mean MD was  $-1.76 \pm 1.5$  dB while mean PSD was  $2.19 \pm 1.5$  dB. In the study by Lopez-Pena et al.,<sup>12</sup> mean MD was  $-0.43 \pm 1.28$  dB while mean PSD was  $0.98 \pm 0.71$  dB in the suspected glaucoma group. Since their<sup>12</sup> inclusion criteria for suspected glaucoma group was presence of normal SOP, the mean MD and PSD values might have been found lower than in our study. In the

study using SOP, Heijl et al.<sup>23</sup> included 126 patients with glaucoma and suspected glaucoma and reported mean MD as  $-6.44$  dB. In the study by Heijl et al., the higher mean MD value may be due to inclusion of patients with diagnosis of glaucoma. In the study, Hoh et al.<sup>11</sup> included 78 eyes from 17 normal patients, 23 patients with ocular hypertension and 38 patients with glaucoma. Authors found that mean MD was  $-0.1 \pm 1.3$  dB,  $-0.9 \pm 1.5$  dB and  $-7.7 \pm 6.9$  dB while mean PSD was  $1.1 \pm 0.5$  dB,  $1.1 \pm 0.6$  dB, and  $7.3 \pm 4.1$  dB in the groups, respectively.<sup>11</sup> In the study by Hoh et al.,<sup>11</sup> the higher mean MD and PSD values may be inclusion of patients with OHT and glaucoma. In our study, only patients with suspected glaucoma were included.

Standard visual field testing as well as optic nerve head and retinal nerve fiber analyzers are being intensively used to minimize challenges in the diagnosis and management of glaucoma.<sup>10</sup> In our study comparing SOP values and RNFL thickness as measured by OCT, no significant correlation was found between SOP and OCT findings (Spearman's  $\rho > 0.05$ ). In a study by Dursun et al. evaluated 84 eyes of 72 patients with early, moderate and advanced glaucoma and found a significant positive correlation between GA indices (MD, PSD) and OCT parameters.<sup>10</sup> Hoh et al. found a significant correlation between RNFL thicknesses and perimetry indices (particularly MD).<sup>11</sup> In their study,

Lopez-Pena et al.<sup>12</sup> suggested that there was a mild-to-moderate correlation between structural and functional data based on the assessment using OCT and SOP with

stronger correlation in patients with suspected glaucoma and those with glaucoma. Unlike studies by Dursun et al.<sup>10</sup> and Hoh et al.,<sup>11</sup> lack of correlation between data from these evaluations may be due to fact that the above-mentioned studies were performed in patients with diagnosis of glaucoma. In the study, Lopez-Pena et al. included patients with normal visual field testing in the suspected glaucoma group. In our study, all patients with suspected glaucoma regardless of visual field testing result. The differences in inclusion criteria might have led differences in outcomes.

This study has some limitations. The diagnosis of glaucoma was made during follow-up by consensus of two ophthalmologists; however, the diagnosis of suspected glaucoma was made by ophthalmologists based on inclusion criteria. In addition, both eyes were included to the study.

In conclusion, no significant correlation was detected between visual field findings (MD, PSD) and RNFL thicknesses as measured by OCT. Clinical examination is essential in the diagnosis of glaucoma and follow-up.<sup>4</sup> In this patient group, visual field testing and RNFL thickness measurement by OCT should be performed for definitive diagnosis of glaucoma, which should be assessed together with clinical presentation. Further studies with larger population will allow more comprehensive outcomes in this field.

**Conflict of interest:** Authors declare no conflict of interest.

**Financial disclosure:** No funding

## REFERENCES

1. Abramoff MD, Garvin MK, Sonka M. Retinal imaging and image analysis. *IEEE Reviews in Biomedical Engineering* 2010;3:169-208.
2. Casson RJ, Chidlow G, Wood JP, et al. Definition of glaucoma: clinical and experimental concepts. *Clin Exp Ophthalmol* 2012;40:341-9.
3. Quigley HA, Broman AT. The number of people with glaucoma worldwide in 2010 and 2020. *Br J Ophthalmol* 2006;90:262-7.
4. Ayhan Z, Arıkan G, Günenç Ü, ve ark. Primer açık açılı glokom, normal tansiyonlu glokom ve oküler hipertansiyonda Humphrey görme alanı, optik koherens tomografi ve heidelberg retina tomografi parametrelerinin korelasyonu. *Türk J Ophthalmol* 2011;41:3.
5. Hodapp E, Parrish RK, Anderson DR. *Clinical Decisions in Glaucoma*. 1st ed. US: St. Louis Mosby;1993;52-61.
6. Prum BE Jr, Lim MC, Mansberger SL, et al. Primary Open-Angle Glaucoma Suspect Preferred Practice Pattern® Guidelines. *Ophthalmol* 2016;123:112-51.
7. Chang RT, Singh K. Glaucoma suspect: Diagnosis and management. *Asia Pac J Ophthalmol (Phila)* 2016;5:32-7.
8. Ahmad SS. Glaucoma suspects: A practical approach. *Taiwan J Ophthalmol* 2018;8:74-81.
9. Jampel HD, Frick KD, Janz NK, et al. Depression and mood indicators in newly diagnosed glaucoma patients. *Am J Ophthalmol* 2007;144:238-44.
10. Dursun B, Keklikçi S.U, Dursun M.E, ve ark. Primer Açık Açılı Glokom Tanı ve Takibinde Bilgisayarlı Görme Alanı ile Optikal Koherens Tomografinin Karşılaştırılması. *Dicle Tıp Dergisi* 2016;43:441-51.
11. Hoh ST, Greenfield DS, Mistlberger A, et al. Optical coherence tomography and scanning laser polarimetry in normal, ocular hypertensive, and glaucomatous eyes. *Am J Ophthalmol*. 2000;129:129-35.
12. Lopez-Pena MJ, Ferreras A, Larrosa JM, et al. Relationship Between Standard Automated Perimetry and Retinal Nerve Fiber Layer Parameters Obtained With Optical Coherence Tomography. *J Glaucoma* 2011;20:422-32.
13. Sommer A, Katz J, Quigley HA, et al. Clinically detectable nerve fiber layer atrophy precedes the onset of glaucomatous field loss. *Arch Ophthalmol* 1991;109:77-83.
14. Sommer A, Miller NR, Pollack I, et al. The nerve fiber layer in the diagnosis of glaucoma. *Arch Ophthalmol* 1977;95:2149-56.
15. Abecia E, Pinilla I, Go'mez ML, et al. Early changes in ocular hypertensive eyes (automated perimetry and retinal nerve fiber layer). *Ann Ophthalmol* 1995;27:203-08.
16. Chen TC, Hogue A, Junk AK, et al. Spectral-domain OCT: helping the clinician diagnose glaucoma. A report by the American Academy of Ophthalmology. *Ophthalmology* 2018;125:1817-27.
17. Stagg BC, Medeiros FA. A Comparison of OCT parameters in Identifying Glaucoma Damage in Eyes Suspected of Having Glaucoma. *Ophthalmol Glaucoma* 2020;3:90-6.
18. Varma R, Lee PP, Goldberg I, et al. An assessment of the health and economic burdens of glaucoma. *Am J Ophthalmol* 2011;152:515-22.
19. Akman A. Role of Optical coherence tomography in Glaucoma. In: Akman A, Bayer A, Nouri-Mahdavi K. *Optical Coherence Tomography in Glaucoma*. Springer, Switzerland, 2018;13-27.
20. Leung CK, Cheung CY, Weinreb RN, et al. Retinal nerve fiber layer imaging with spectral-domain optical coherence tomography: a variability and diagnostic performance study. *Ophthalmology* 2009;116:1257-63.
21. Bayraktar Ş, Türker G. Erken glokom ve glokom şüphesi olgularında optik koherens tomografi ile elde edilen retina sinir lifi kalınlığı ölçümlerinin tekrarlanabilirliği. *Türk J Ophthalmol* 2000;30:404- 8.
22. Resnikoff S, Pascolini D, Etya'ale D, et al. Global data on visual impairment in the year 2002. *Bull World Health Organ* 2004;82:844-51.
23. Heijl A, Patella VM, Chong LX, et al. A New SITA Perimetric Threshold Testing Algorithm: Construction and a Multicenter Clinical Study. *Am J Ophthalmol* 2019;198:154-65.