

Spontaneous Late Anterior Dislocation of Intraocular Lens within the Capsular Bag in Pseudoexfoliation Syndrome

Psödoeksfolyasyon Sendromunda Kapsüler Bag İçindeki Göz İçi Lensin Spontan Geç Öne Dislokasyonu

Berna ÖZKAN¹, Özgül ALTINTAŞ², Nurşen YÜKSEL³, Yusuf ÇAĞLAR³

Case Report

Olgu Sunumu

ABSTRACT

A 77-year-old pseudoexfoliation syndrome patient presented with sudden reduction in vision in her left eye for 2 days. The patient had a history of cataract surgery 8 years ago. In biomicroscopic examination it was found that the posterior chamber intraocular lens within the capsular bag was dislocated anteriorly through the pupillary space to anterior chamber, and pseudoexfoliative material was present on the lens capsule and the zonules. Patients with pseudoexfoliation syndrome may be at risk for delayed spontaneous dislocation of PC-IOL within capsular bag posteriorly several years after cataract surgery. PC-IOL within capsular bag may rarely dislocate to the anterior chamber in those patients.

Key Words: In the bag anterior dislocation, intraocular lens, pseudoexfoliation.

ÖZ

Yetmiş yedi yaşında, pseudoeksfolyasyon sendromu olan bir hasta sol gözünde 2 gün önce başlayan ani görme azalması ile kliniğimize başvurdu. Hastanın hikayesinde 8 yıl önce geçirilmiş katarakt operasyonu bulunmaktaydı. Biyomikroskopik muayenede hastanın sol gözündeki arka kamara intaoküler lensin üzerinde pseudoeksfolyasyon materyalleri bulunan kapsül ile beraber pupilla aralığından ön kamaraya disloke olduğu görüldü. Psödoeksfolyasyonu olan hastalarda, katarakt cerrahisinden yıllar sonra arka kamara göz içi lensinin etrafında kapsüler bag ile beraber geriye doğru disloke olma riski mevcuttur. Bu hastalarda arka kamara göz içi lensi nadiren ön kamaraya da disloke olabilir.

Anahtar Kelimeler: Bag içi öne dislokasyon, göz içi lens, psödoeksfolyasyon.

Glo-Kat 2008;3:268-269

INTRODUCTION

Progressive zonular weakness and potential for dislocation of crystalline lens spontaneously, during cataract surgery or following trauma are well known features of pseudoexfoliation syndrome (PXS). Recently, spontaneous late in the bag posterior dislocation of intraocular lens in several cases have been reported.¹⁻³ We present a case with spontaneous anterior dislocation of in the bag intraocular lens 8 years after cataract surgery.

Geliş Tarihi : 12/09/2008

Kabul Tarihi : 24/12/2008

Received : September 12, 2008

Accepted : December 24, 2008

- 1- Kocaeli Üniversitesi Tıp Fakültesi, Göz Hastalıkları A.D., Kocaeli, Yard. Doç. Dr.
- 2- Kocaeli Üniversitesi Tıp Fakültesi, Göz Hastalıkları A.D., Kocaeli, Doç. Dr.
- 3- Kocaeli Üniversitesi Tıp Fakültesi, Göz Hastalıkları A.D., Kocaeli, Prof. Dr.

- 1- M.D., Kocaeli University Faculty of Medicine, Department of Ophthalmology Kocaeli/TURKEY
ÖZKAN B., berna.ozkan@kocaeli.edu.tr
- 2- M.D. Associate Professor, Kocaeli University Faculty of Medicine, Department of Ophthalmology Kocaeli/TURKEY
ALTINTAS Ö., ozgulaltintas@yahoo.com
- 3- M.D. Professor, Kocaeli University Faculty of Medicine, Department of Ophthalmology Kocaeli/TURKEY
YÜKSEL N., nursencemre@e-kolay.net
ÇAĞLAR Y., yusuf@kou.edu.tr

Correspondence: M.D., Selim DEMİR

İlyasköy Mahl. Yenice Sokak No: 10/7 Samsun/TURKEY

CASE REPORT

A 77-year-old woman who had undergone cataract extraction and posterior chamber intraocular lens implantation in both eyes 8 years previously was referred to our clinic. Postoperatively, the patient noted improved vision that remained asymptomatic until 2 days before presentation when she complained of sudden reduction in vision in her left eye. Recent trauma or a laser treatment histories were not present. Examination of patient revealed a best corrected visual acuity of 20/100 in her right eye (RE) and counting fingers from 2 meters in her left eye (LE). Intraocular pressures were RE: 10 mmHg and LE: 12 mmHg. The posterior chamber IOL was subluxated inferiorly and temporally in RE. Fine white deposits consistent with PXS were present on the anterior capsulorhexis. Pseudoexfoliation was also noted. In LE the IOL entirely within capsular bag was almost completely dislocated anteriorly through the pupillary space into anterior chamber, and pseudoexfoliative material was present on the lens capsule and the zonules. The haptic of IOL in the anterior chamber was almost in touch with cornea. There were minimal cells in the anterior chamber and cornea was slightly edematous. The cup-to-disc ratio was 0.4 and several hard exudates in macular region were present in both eyes. The encapsulated 3 piece PMMA IOL with flexible haptics was retrieved from the anterior chamber and anterior vitreous, and explanted. A + 19.0 D anterior chamber IOL was implanted after an anterior vitrectomy and performing peripheric iridectomy. In the early postoperative period minimal anterior chamber inflammation was observed. The pseudophakic corrected visual acuity of the patient was 20/63 at the end of the postoperative first week.

DISCUSSION

Contraction of anterior capsule¹ and progressive weakening of zonules² that are more pronounced in eyes with pseudoexfoliation patients, may contribute to spontaneous late capsular bag and IOL dislocation. In pseudoexfoliation, the zonules become weak due to degenerative process at the interface of the zonules to the basement membrane of the ciliary processes.³ Additionally, af-

ter cataract surgery some degree of capsular contraction may take place resulting in reduction in the aperture of capsulotomy and shrinkage of the diameter of the capsular bag. An extreme degree of contraction has been called "capsule contraction syndrome."⁴ Capsule contraction syndrome may result in stress in the zonules which may lead to "in the bag dislocation" of the IOL. The IOL usually dislocate to the vitreous cavity¹, however rarely it might dislocate to the anterior chamber as in our case.

IOL material is an important factor that effects "in the bag IOL dislocation" related to the of capsule contraction. It has been showed that capsular contraction secondary to anterior capsule opacification is greatest with plate haptic silicone-IOL and least with acrylic hydrophobic IOLs.⁵ Our patient had 3 pieced PMMA IOL with flexible haptics which might not have enough resistance against postoperative shrinkage of the capsule. It can be hypothesized that a single pieced rigid PMMA IOL might maintain better stabilization of the IOL in patients with pseudoexfoliation.

A couple of precautions can be taken in order to reduce the risk of "in the bag dislocation" of the IOL in eyes with pseudoexfoliation syndrome. Alternatives to in the bag implantation like sulcus implantation of IOL or implantation of IOL with capsular ring should be considered. The capsular rings with a fixation hook attached to the sclera can also be helpful to eliminate the risk of dislocation.

KAYNAKLAR/REFERENCES

1. Jeffrey GG, Gregg TK, Weinberg DV.: In-the-bag intraocular lens dislocation. *Am J Ophthalmol.* 2004;137:630-635.
2. Masket SM, Osher RH.: Late complications with intraocular lens dislocation after capsulorhexis in pseudoexfoliation syndrome. *J Cataract Refract Surg.* 2002;28:1481-1484.
3. Jehan FS, Mamalis N, Crandall AS.: Spontaneous late dislocation of intraocular lens within the capsular bag in pseudoexfoliation patients. *Ophthalmology.* 2001;108:1727-1731.
4. Davison JA.: Capsule contraction syndrome. *J Cataract RefractvSurg.* 1993;19:582-589.
5. Werner L, Pandey SK, Apple DJ, et al.: Anterior capsule opacification: correlation of pathologic findings with clinical sequelae. *Ophthalmology.* 2001;108:1675-1681.

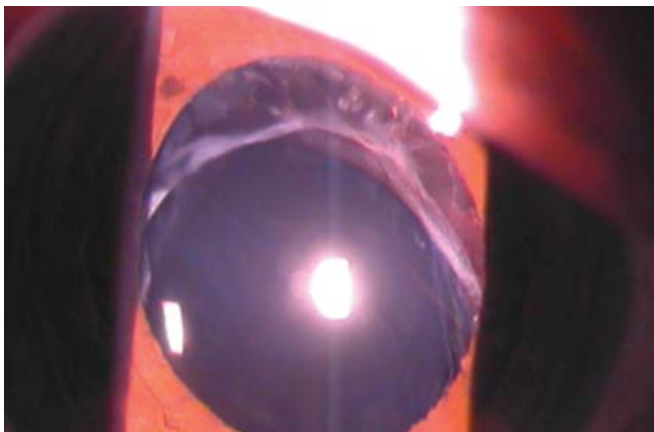

Figure 1: Clinical photograph of IOL in the right eye decentrated inferiorly and temporally, and the pseudoexfoliative material on anterior capsule.

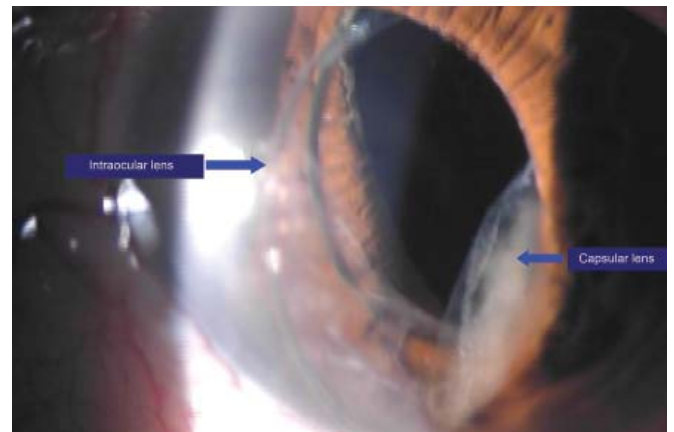


Figure 2: Clinical photograph before removal of the IOL-capsular bag complex dislocated anteriorly through pupillary space in the left eye.